




Utility of a novel high pressure non-compliant balloon for tibial atherosclerotic lesions in Asian patients with chronic limb threatening ischaemia

Tjun Yip Tang^{1,2} , Shaun Qing Wei Lee¹, Sze Ling Chan³, Charyl Jia Qi Yap¹, Shereen Xue Yun Soon¹, Tze Tec Chong^{1,2}, Edward Tieng Chek Choke⁴, and Bryan P.Y. Yan⁵

¹ Department of Vascular Surgery, Singapore General Hospital, Singapore

² Duke-NUS Graduate Medical School, Singapore

³ Health Services Research Center, SingHealth, Singapore

⁴ Department of General Surgery, Sengkang General Hospital, Singapore

⁵ Division of Cardiology, Prince of Wales Hospital, Hong Kong SAR, China

Summary: *Background:* The aim was to evaluate the safety and efficacy of a high pressure, non-compliant balloon in the treatment of infrapopliteal occlusive disease in Asian patients with chronic limb threatening ischaemia (CLTI) from Singapore. *Patients and methods:* Prospective, multi-centre, single arm, non-randomized study. Immediate technical success, 6-month primary vessel patency (determined by Duplex ultrasonography), limb salvage, one-year clinically driven target lesion re-intervention (TLR) and amputation free survival (AFS) were the efficacy endpoints of interest. *Results:* 86 patients (63% males, mean age 68.9 ± 9.9 years) were enrolled over a 15-month period. Diabetes mellitus (DM) and end-stage renal failure (ESRF) were present in 94% and 38% of patients respectively. All had some degree of tissue loss at baseline (Rutherford scale 5 and 6 = 91% and 9% respectively). Of the 86 legs, 72% had 3 crural vessel disease and 84% had moderate/severe vessel wall calcification. 90% had > 1 TASC D tibial lesion. Acute technical success was 89%. One month mortality was 3.5% and one-year freedom from TLR was 91%. 6-month tibial patency was 73%. 54/66 (82%) patients had at least one target treated tibial artery open at 6 months. A lower baseline toe pressure (OR 1.03, 95%CI 1.00–1.05) and elastic recoil post angioplasty (OR 0.20, 95%CI 0.05–0.79) were associated with a worse 6 month tibial patency. One-year AFS was 67%. 47/66 (71%) patients had a clinical improvement of at least one Rutherford class at 6 months and 52/59 (88%) experienced complete wound healing at 12 months. *Conclusions:* Use of a high pressure non-compliant balloon is safe and efficacious in treating highly complex infra-popliteal atherosclerotic lesions in an otherwise challenging population of CLTI patients with a high incidence of DM and ESRF. It is associated with highly satisfactory acute technical success, 6-month target lesion patency and one-year limb salvage.

Keywords: JadeTM, non compliant balloon, high pressure, percutaneous angioplasty, chronic limb threatening ischaemia, limb salvage, outcome

Introduction

Chronic limb threatening ischemia (CLTI) has become a global epidemic and represents the most advanced stage of peripheral artery disease (PAD), which if left untreated, can progress to ulceration, gangrene, sepsis, major lower extremity amputation (LEA) and premature death [1]. Patients with CLTI usually present with multi-level PAD and infra-popliteal arterial occlusions and endovascular therapy have become the preferred modality to restore pulsatile blood flow to the foot [2]. Despite high rates of

technical success (> 90%), tibial angioplasty is plagued by high rates of re-occlusion/stenosis because of elastic recoil [3] and barotrauma caused by intra-arterial ballooning, which leads to the development of neointimal hyperplasia (NIH) [4]. Restenosis affects clinical outcomes of CLTI patients undergoing tibial angioplasty [5] and accounts for high rates of clinically indicated target lesion revascularization (TLR) procedures [6]. Re-stenosis has been observed within three months of plain balloon angioplasty (POBA) in more than two thirds of patients [7, 8] and TLR may be as high as 48% within a year [6, 8]. This

becomes important because tibial artery patency has been shown to be directly related to clinically relevant endpoints such as wound healing, major LEA and mortality [5, 8].

Devices coated with paclitaxel have been used successfully in the clinical arena to limit restenosis by inhibiting the biologic pathway that leads to NIH [9]. However, recent systematic reviews and study-level meta-analyses of randomized controlled trials investigating treatment of the infra-popliteal arteries with paclitaxel-coated balloons (PCB) compared with conventional POBA for CLTI either showed no significant differences in limb salvage, survival, restenosis, TLR, and amputation-free survival (AFS) between the two groups [10] or was significantly worse in those who had PCB [11]. Current poor patency seen in tibial angioplasty is also likely contributed in part by small vessel size, especially pertinent to Asian tibial arteries, and poor luminal gain after standard semi-compliant POBA. Early elastic recoil is frequent and substantial [3] in CLTI patients because the tibial atherosclerotic lesions are often complex, long and calcified and although PCB may have the potential to mitigate the NIH response, their benefit in addressing the problem of acute recoil is doubtful. To lower the restenosis risk due to early recoil, prolonged angioplasty and the application of mechanical scaffolding with stents have been shown to be supportive in the coronary bed [4]. However, the use of bare metal stents (BMS) has not been shown to be superior compared to POBA in infra-popliteal lesions [12] because implantation of tibial BMS are thought to promote NIH, outweighing the benefit of mechanical scaffolding. Hence, vessel preparation and optimising POBA with high pressure, non-compliant balloons, which allow greater forces to be applied focally without overstressing other parts of the diseased segment of vessel, may help achieve better luminal gain for rapid and sustained blood flow for wound healing.

The aim of this study was to evaluate the safety and efficacy of the Jade™ (OrbusNeich, Hong Kong) high pressure non-compliant balloon in the treatment of infrapopliteal occlusive disease in Asian patients with CLTI from Singapore. Technical success, six-month Duplex-defined tibial vessel patency and clinical outcome are presented.

Patients and methods

Study design

This is a multi-centre, single investigator, single-arm prospective study investigating the use of the Jade™ (OrbusNeich, Hong Kong) high pressure, non-compliant balloon in a cohort of multi-ethnic Asian patients with CLTI (Rutherford category 5 to 6), who had stenotic (>50% on Duplex ultrasound) or occlusive infra-popliteal atherosclerotic disease and at least a single tibial vessel run-off to ankle on angiography. Although previous ipsilateral conventional POBA was allowed, those who had previous tibial artery stenting were not included. Ethical approval was gained from the Institution Review Board (CIRB ref

number: 2018/2995). The study was conducted in accordance with good clinical practice standards and the ethical principles of the Declaration of Helsinki and its amendments. Informed consent was obtained from each patient according to institutional protocol for patients undergoing percutaneous angioplasty procedures between November 2017 to January 2019 at Singapore General Hospital, (SGH), a tertiary vascular centre in central Singapore and at Sengkang General Hospital, the newest restructured hospital situated in the north-east of the Island. SGH, the lead centre, performs over 900 lower limb angioplasty procedures annually with over 95% cases for limb salvage. Data were collected prospectively onto a secure computer database using a dedicated proforma, with a telephone questionnaire conducted if required for subsequent clinic follow-up non attendance. All patients had at least one year of follow-up.

Pre-morbid variables collected included patient demographics, co-morbidities, tissue loss severity based on the Rutherford scale [13] and pre-operative toe pressure. Procedural data included TASC lesion severity, number of tibials treated, the degree of tibial calcification and how the Jade™ balloon performed in terms of vessel recoil, slippage and trackability through the lesion. Outcomes measured included major adverse clinical events (MACE), subsequent major LEA, clinical TLR, 6-month tibial patency, wound healing rates at 3, 6, 12 months and 12-month AFS. Patients with a target tibial reference diameter of 1.5–3.5 mm were included in the study.

Procedure

An arterial Duplex ultrasound of the index limb and toe pressure measurements were obtained prior to all interventions. All patients were seen by cardiology and nephrology for optimization of medications and risk profile pre-operatively.

PTA was performed by the senior author (TYT) in a fixed imaging hybrid operating room either under local, regional or general anaesthetic depending on patient compliance, the complexity of the procedure and whether a concomitant ray amputation(s) or wound debridement were also required. Intravenous antibiotics were routinely administered at induction. Standard digital subtraction techniques were employed to maximize image quality while minimizing use of contrast agent. Carbon dioxide angiography was used in patients with contrast allergy or poor renal function. An ipsilateral antegrade common femoral approach was preferred for infra-inguinal and infrapopliteal stenotic and/or occlusive lesions. Contralateral up and over approach was only adopted when severe disease of the ipsilateral common femoral artery precluded ipsilateral antegrade puncture, or when concomitant iliac lesions needed to be treated. Intra-arterial heparin (2000–5000 IU) was routinely administered via the intra-arterial sheath (usually 5Fr Avanti™ + sheaths, Cordis, Baar, Switzerland) only after a diagnostic angiogram had been performed and angioplasty was intended. Trans-luminal crossing of the stenosis or occlusion was performed if

possible. There was a low threshold to adopt a subintimal crossing technique when intra luminal crossing was unsuccessful, especially in the more calcified lesions. When antegrade lesion crossing failed, retrograde crossing from a distal puncture site was achieved. Distal access was usually obtained using a micropuncture needle (Micropuncture® Access set, Cook Medical, Bloomington, IN, US) under ultrasound guidance. Femoro-popliteal and infra-popliteal lesions were initially crossed using an 0.018 inch hydrophilic guidewire (V18, Boston Scientific, Massachusetts, USA) and once lesion crossing was confirmed, this was switched to a 0.014" wire (Command ES, Abbott Vascular, Santa Clara, CA, US) to use the Jade™ balloon platform. POBA was applied to both supra- and infra-popliteal lesions with bail-out stenting used selectively for flow-limiting and spiral post PTA dissections and/or significant recoil (>30%). All infra-popliteal lesions were exclusively treated with the Jade™ balloon but the use of semi-compliant and paclitaxel coated balloons for the femoral-popliteal segments was allowed at the senior author's (TYT) discretion. Control angiography was performed in two orthogonal projections to assess for recoil and/or dissections. Use of drug-eluting balloons was not performed in this study for the infrapopliteal arteries. All patients received at least a single antiplatelet therapy post-angioplasty.

Follow-up

Clinical evaluation and outcomes are reported up to 12 months. Clinical assessments were performed at 1, 3, 6 and 12 months after their procedure to assess clinical progress and wound healing. There was a mandatory 6-month Duplex ultrasound to check tibial artery patency.

Primary and secondary endpoints

Complication-free survival at one month was the safety endpoint evaluated. Primary patency, limb salvage and the need for re-intervention at 12 months were the efficacy endpoints of interest. Secondary endpoints captured included 1-year mortality, improvement in Rutherford scale and major amputation of the operated limb.

Jade™ catheter balloon

This is a true non-compliant balloon that is deployed over an 0.014" wire platform, designed for treating peripheral vascular atherosclerotic lesions. Jade™ has a 60 cm lumen tracking section, making it a hybrid rapid exchange/over-the-wire construction allowing for extra pushability for more distal lesions. It has a high burst pressure (22 RBP) aimed for opening more calcified and resistant lesions. It has a low balloon compliance for controlled opening of resistant lesions and allows for safe and precise inflation. There is minimal diameter growth even at burst pressure. The catheter was available with balloon diameter sizes 2.0, 2.5, 3.0, 3.5, 4.0, 5.0 and 6.0 mm and lengths of 40, 80, 120, 180, 240 mm, with a working shaft length of 150 cm. The size of the catheter was selected to approximate 1:1 ratio of the nominal balloon inflation diameter to the reference vessel of each lesion treated. The balloon

was prepped according to standard procedures for POBA catheters by negative aspiration followed by attachment to the balloon inflation port of an inflation device (20/30 Indeflator Inflation Device, Abbott Vascular, Santa Clara, CA, US), containing 1:1 mixture of radiographic contrast and normal saline. Balloons were inflated routinely for 120 seconds and for 180 seconds for longer (> 20 cm) severely calcified lesions. The senior author (TYT) prefers using the longer balloons in the various sizes (180 mm and 240 mm) for the longer complex calcified complete total occlusions (CTO). This reduces the risk of dissection and recoil and optimises concentration of the dilating force equally along the diseased infrapopliteal tibial vessel.

Definitions

Acute technical success was defined as the ability to deliver and inflate the balloon to the intended target tibial lesion as planned and achieve final residual stenosis < 30% without flow limiting dissection and without requiring bailout stenting. Major LEA was defined to be any amputation above the ankle. Amputation Free Survival (AFS) was defined as survival without major LEA. The extent of CLTI was categorized using the Rutherford classification [13] (Rutherford 5: non-healing ulcer, Rutherford 6: gangrene). Lesion calcification was graded according to the presence of radio-opacities within the arterial wall at the site of occlusion or stenosis as per Dattilo [14]: mild = minimal calcium noted < 180° and < 50% length of target vessel; moderate = < 180° and > 50% length of target vessel; severe = diffuse radio-opacities noted on both sides of the arterial wall / > 180° and > 50% length of target vessel. Device slippage was assessed using a semi-quantitative scale. This included no slippage (no visible movement of the balloon at the target lesion immediately prior to inflation and during the first inflation); slight slippage (>5 mm of balloon movement with the device still straddling the target lesion segment); moderate slippage (>5 mm balloon movement but remains within the target lesion segment) and severe slippage (the balloon moves > 5 mm and outside the target lesion segment). Primary patency was defined as having been maintained if the patient did not require further infra-popliteal intervention and if the Duplex scan did not show a significant restenosis (peak velocity ratio ≥ 2.5 , which is indicative of > 50% diameter stenosis).

Statistical analysis

Baseline variables were summarised with the use of descriptive statistics. Continuous variables were reported as the mean and standard deviation, or median and range, as appropriate, and categorical variables as absolute number and percent. We then tested for the association between baseline and operative characteristics and angioplasty outcomes using univariate logistic regression. Variables with $p < 0.05$ were then combined into a multivariate logistic regression model. All analyses were performed in R version 3.5.1 [15].

Results

Patient demographics

86 patients (129 tibial lesions) were enrolled over a 15-month period. 59/86 (63%) were males and mean age was 68.9 ± 9.9 years. 81/86 (94%) had diabetes mellitus, 65/86 (76%) had some degree of chronic renal impairment and 33/86 (38%) had end-stage renal failure (ESRF) at baseline. The majority were frail patients with American Society of Anesthesiologists (ASA) grade 3 (78/86 (91%)) and 50/86 (58%) presented with anaemia. All patients had some degree of tissue loss (Rutherford category 5 = 78/86 (91%) and Rutherford category 6 = 8/86 (9.3%)) and median presenting toe pressure of the affected foot was 39 mmHg (range 0–109). Table I shows subject demographics and baseline clinical characteristics.

Lesion characteristics

77/86 (90%) patients had at least one TASC D tibial lesion; 47/86 (55%) had at least one tibial occlusion and 46/86 (54%) a tibial atherosclerotic lesion greater than 20 cm in length. 62/86 (72%) had 3 crural vessel disease. Lesion morphology was complex with a high incidence (72/86; 84%) moderate/severe vessel wall calcification. Majority of patients (68/86; 79%) had multi-level infrainguinal disease with concomitant superficial femoral/popliteal artery involvement. Infra-malleolar disease was treated in 30/86 (35%) legs. The anterior tibial artery (ATA) (Figure 1) was the most treated vessel (63/129; 49%). Table II shows tibial lesion characteristics and intra-operative data.

Balloon performance

The Jade™ PTA balloon was effectively delivered to and inflated at the intended tibial lesion in 127/129 (98%) cases. The two failed cases of tracking the balloon to the intended lesion site were because of severe calcification proximally in the tibial artery, which did not permit the balloon to pass. These required a through and through wire to pull the balloon down from a retrograde position (badform technique) [16]. There were only two cases (2/129; 1.5%) of moderate balloon slippage during inflation and again these were in complex severely calcified lesions with long (>20 cm) CTOs. The average inflation pressure used was 18 atm (range 12–22 atm). 29/129 (22%) dissections were noted; the majority (23/29; 79%) were mild or moderate in nature and were non-flow limiting and were just reballooned for a prolonged period (3 minutes) and did not lead to significant luminal compromise. 6/29 (21%) were spot stented with a drug eluting stent with an overall bailout stenting rate of 9/129 (7.0%) lesions, inclusive for severe recoil. Recoil was noted in 12/129 (9.3%) vessels with 4 cases leading to early major LEA. Acute technical success was therefore 115/129 (89.1%). There was one arterial perforation (1/129; 0.8%) in the mid segment of a severely calcified posterior tibial artery. This occurred with a 3.5 mm diameter balloon and on reflection this was slightly oversized for the reference vessel diameter. There was no adverse clinical sequelae and the extravasation stopped with

Table I. Baseline demographics and clinical characteristics

Characteristic	n (%)
Age, mean (SD)	68.9 (± 9.9)
Male gender	54 (62.8)
Smoking	
Never-smoked	49 (57.0)
Smoker	15 (17.4)
Ex-smoker	22 (25.6)
Comorbidities	
Coronary artery disease	53 (61.6)
Congestive heart failure	17 (19.8)
Chronic renal impairment	65 (75.6)
End stage renal failure	33 (38.4)
Diabetes mellitus	81 (94.2)
Body mass index	
< 20	16 (18.6)
20–30	58 (67.4)
> 30	12 (14.0)
Hemoglobin (g/dl)	
< 10	50 (58.1)
≥ 10	36 (41.9)
CLTI treatment history	
Previous bypass or angioplasty	23 (26.7)
Previous minor amputation	16 (18.6)
Previous contralateral major amputation	3 (3.5)
Living at home prior to admission	81 (94.2)
Admitted through emergency department	48 (55.8)
ASA score	
1	1 (1.2)
2	7 (8.1)
3	78 (90.7)
Rutherford score	
5	78 (90.7)
6	8 (9.3)
Toe pressure (mmHg), median (range)	39 (0–109)

ASA: American Society of Anesthesiologists; CLTI: Chronic Limb Threatening Ischemia; SD: Standard deviation.

prolonged ballooning. There were no instances of retained device components, embolization or device-related deaths.

Outcome

Mortality at 1, 6 and 12 months after their index procedure were 3/86 (3.5%), 11/86 (12.8%) and 17/86 (19.8%), respectively. Peri-procedural complication rate was 13/86 (15.1%). There were 11/86 (12.8%) cases of deterioration in renal function post procedure attributable to contrast induced nephropathy. The majority (8/11; 72.7%) were in those with pre-existing chronic renal impairment. At 12 months, freedom from TLR was 78/86 (90.7%). Lesion base analysis showed that 6-month tibial patency was 69/94 (73.4%). On a patient level, 54/66 (81.8%) had at least one target tibial open at 6 month follow-up. One-year amputation free survival was 59/86 (68.6%). There were 16/86 (18.6%) major LEA at one year. 51/86 (59.3%) patients were alive at 2 years. Complete wound healing at 3, 6 and 12 months were 22/78 (28.2%), 46/66 (66.7%),

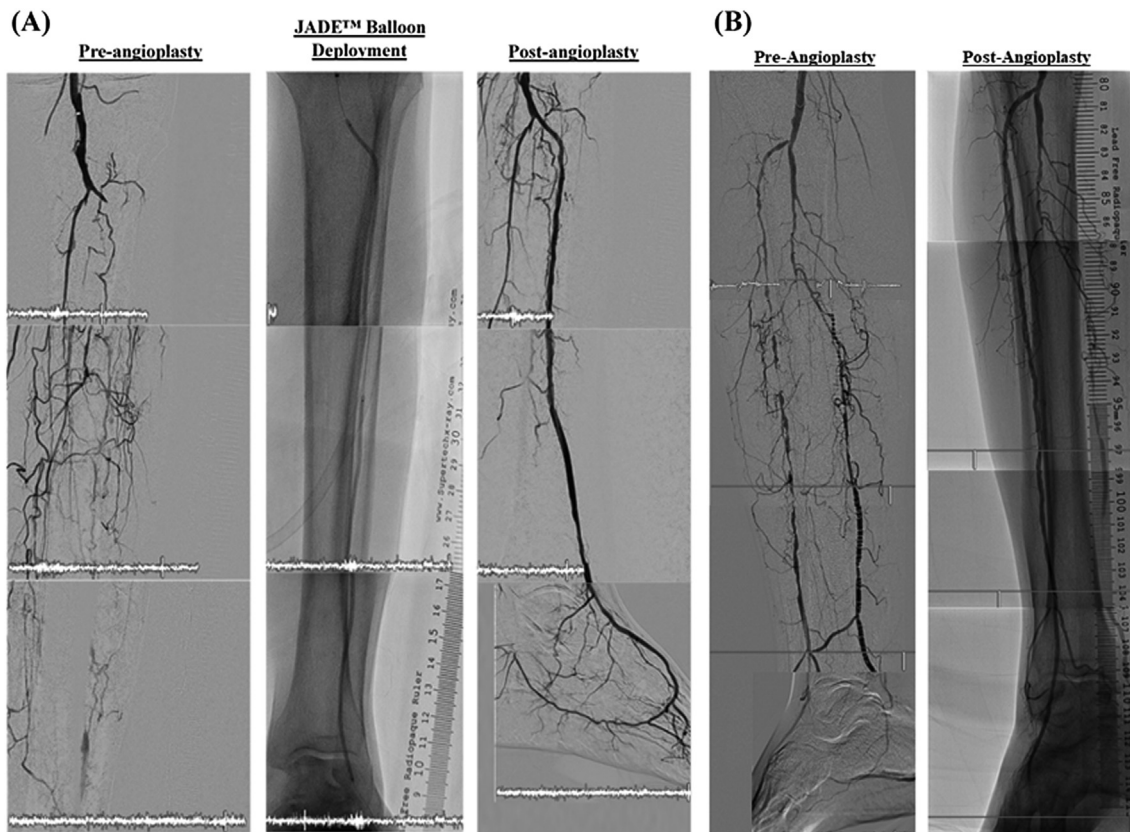


Figure 1. An example of a typical diabetic with renal impairment undergoing a (A) left anterior tibial artery (ATA) angioplasty for a long ATA occlusion (>20 cm) with JADE™ 2.5 mm × 240 (distal) and 3.0 mm × 120 (proximal) at high pressure (20ATM) showing an excellent luminal gain and outflow result. This was followed by (B) a right long ATA recanalization procedure with a 3 mm × 240 mm Jade™ balloon at 18ATM with a similar excellent luminal gain result.

52/59 (88.1%) respectively. 47/66 (71%) patients who were alive and still had their leg intact at 6 months experienced a clinical improvement of at least one Rutherford class.

Low baseline toe pressure (OR 1.03, 95%CI 1.00–1.05) and immediate elastic recoil post angioplasty (OR 0.20, 95%CI 0.05–0.79) were associated with a worse 6 month tibial patency on multivariate regression. The number of diseased tibials at index procedure was associated with poor wound healing at 3 (OR 0.38, 95%CI 0.14–0.99) and 6 (OR 0.30, 95%CI 0.11–0.85) months. At 12 months, the severity of tibial disease did not become significant and only Hb \geq 10 (OR 4.01, 95%CI 1.21–13.31) and living at home pre-morbidly (OR 16.54, 95%CI 1.53–178.33) were associated with a better wound healing outcome (Figure 2).

Discussion

PTA is still considered the standard of care for below the knee (BTK) tibial endovascular interventions in CLTI patients, given its relatively minimally invasive nature over open surgical bypass in what is a challenging and frail population of patients with multiple co-morbidities [1]. Furthermore, the atherosclerotic lesions in CLTI tend to be multi-level, multi-vessel in distribution with a predomi-

nance of long CTOs over stenotic lesions, which are more amenable to be tackled with wire-based interventions [2]. Despite the increasing popularity of an endovascular first approach to CLTI, the Achilles heel of tibial angioplasty is acute elastic recoil and barotrauma leading to NIH and restenosis and subsequent loss in lumen patency. Loss of arterial patency is associated with poorer outcomes such as delayed wound healing, higher major LEA, need for clinically driven TLR and death [5] and refutes the well accepted “tide-over” concept, which hypothesizes that infrapopliteal patency was only necessary for the duration of ulcer/wound healing but not thereafter for the maintenance of skin integrity [17], supported by the fact that there is higher limb salvage rates compared to primary vessel patency after an intervention [18].

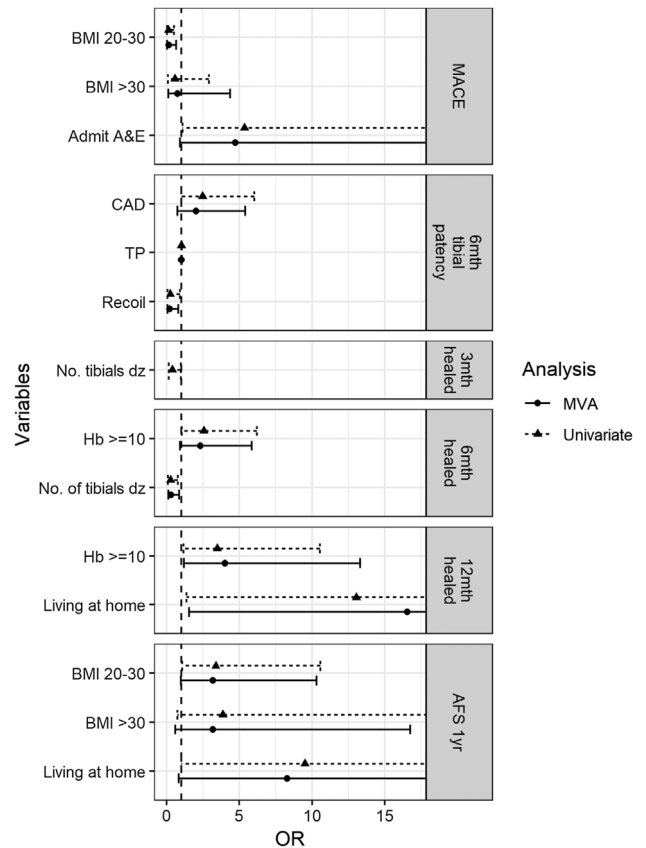
Our data have shown that use of the high pressure non compliant Jade™ balloon is feasible, safe and efficacious with a low incidence of intraprocedural complications. In an all comers cohort, with liberal inclusion and few exclusion criteria, we have demonstrated a low one-month mortality rate (3.5%) and low procedural complication rate (perforation rate < 1%) and high technical success rate (89%). A primary patency rate at 6 months of 73.4% of target tibial lesions compares more favourably to PTA results using semi-compliant balloons [7, 8]. Complete wound healing of 88% at one year follow up is comparable with open surgical results of limb salvage [19].

Table II. Vascular lesion characteristics and operative data summary

Characteristic	n (%)
Vascular lesion characteristics	
TASC	
C	9 (10.5)
D	77 (89.5)
No. of tibials diseased	
1	1 (1.2)
2	23 (26.7)
3	62 (72.1)
Calcification	
Focal/mild	14 (16.3)
Moderate	38 (44.2)
Severe	34 (39.5)
Superior femoral artery/popliteal artery involved	68 (79.1)
Tibial occlusion	47 (54.7)
Tibial lesion > 20 cm	46 (53.5)
Intra-operative data	
No. of tibials treated (n = 129)	
1	49 (38.0)
2	34 (52.7)
3	4 (9.3)
Tibials treated (n = 129)	
Anterior tibial artery	63 (48.8)
Peroneal artery	29 (22.5)
Posterior tibial artery	31 (24.0)
Tibioperoneal trunk	6 (4.7)
No. of balloons used	
1–2	20 (23.3)
3	29 (33.7)
4	32 (37.2)
5–6	5 (5.8)
Below ankle treatment	30 (34.9)
Recoil	12 (9.3)
Balloon slip	2 (1.6)
Dissection	29 (22.5)
Balloon trackability	127 (98.5)
Bailout tibial stenting	9 (7.0)
SAFARI	19 (22.1)
Hybrid	13 (15.1)
Minor amputation	48 (55.8)
Transmetatarsal amputation	13 (15.1)
Hindfoot amputation	21 (24.7)

SAFARI: Subintimal arterial flossing with antegrade-retrograde intervention; TASC: The Inter-Society Consensus for the Management of Peripheral Artery Disease.

Conventional angioplasty using semi-compliant balloons is limited in its ability to adequately treat complex fibrocalcific lesions and to overcome acute elastic recoil of ostial and heavily calcified lesions and small vessel disease [7]. The technique is also associated with frequent balloon slippage resulting in geographical miss. The results are often unpredictable and have a high rate of uncontrolled dissections (>30%). One of the reasons for this is that conventional semi-compliant balloons causes a “dog-boning” effect whereby non-uniform balloon expansion with over dilatation of the more compliant segments at the lesion edges

**Figure 2.** Factors associated with outcome using univariate and multivariate analysis.

leads to increased rate of vessel damage. Furthermore, there is a more pronounced elastic recoil following PTA in diabetic compared to non-diabetic patients and is thought to be due to severe arterial rigidity secondary to higher medial sclerosis and calcification [20]. The geographical miss, balloon slippage and dissection rates were low in our series of patients and is likely due to the non-compliant properties of the balloon and the use of long balloons (180 mm and 240 mm) to give a controlled concentration of the dilating force equally along the diseased infrapopliteal tibial vessel and modify the calcium in the medial layer from the higher forces applied. Fibro-calcific plaques have been shown to reduce vessel distensibility and impair full and uniform balloon dilatation using conventional semi-compliant balloons [21].

The use of non compliant (NC) balloons originated from the coronary literature. They were used to post-dilate coronary stents to achieve optimal expansion and larger lumens, which led to reduced restenosis and stent thrombosis rates [22]. Romagnoli *et al* demonstrated the advantage of achieving better stent expansion using NC balloon post dilatation over semi compliant stent balloons despite achieving the same final balloon size (based on manufacturer's balloon compliance charts) [23]. The NC balloons not only have a linear relationship between the changes in applied pressure and the changes in observed volume ($\Delta V/\Delta P$, the definition of compliance) but also tolerate 50% greater inflation pressures. These combined properties

allow greater forces to be applied focally without overstretching other parts of the diseased segment [24]. When a stent is deployed at high pressures with a semi-compliant stent balloon, it may cause stent edge dissection, coronary perforation and intimal injury leading to an increased inflammatory response and higher restenosis rate. Hence, using an NC balloon for high-pressure post-dilatation stent optimisation is not just physiologically appropriate but technically safer than going up to higher pressures with a compliant balloon. Disadvantages using NC balloons in the coronary bed include the association with higher number of side branch occlusions [25] and potential distal embolization of clot in the acute myocardial infarction setting and microvascular plugging [26], both leading to further myocardial damage. However in the peripheral circulation, side branches are not as relevant compared to the coronary bed and clot is often not a factor in the CLTI setting. NC balloons have also been found to be a useful adjunct in heavily calcified undilatable coronary lesions [27]. It has been shown to be a safe tool for optimal lesion preparation prior to stent deployment even when other technologies such as cutting or scoring balloons have failed to achieve adequate results [28]. Even using higher forces to dilate the resistant stenoses, there were no major complications such as vessel perforation, which is in keeping with what we have found here in our study of peripheral atherosclerotic lesions, with a high incidence of severe wall calcification.

To our knowledge this is the first study formally looking at the utility of NC balloons in the peripheral vasculature. The data from the coronary literature would support their use in the peripheral circulation especially in the setting of CLTI with a heavily incidence of severe lesion calcification and long CTOs. The high pressure afforded by the balloon catheters may attenuate the elastic recoil phenomena associated with normal semi-compliant balloons by overcoming the rigidity the calcium places on the vessel wall. What we have not looked at in this cohort is the use of drug elution to offset the NIH effect from barotrauma. Would this have improved the primary patency of 73% at 6 months? Data using paclitaxel coated balloons (PCB) in tibial lesions are currently conflictory with a recent meta-analysis showing no advantage in terms of limb salvage, survival, restenosis and TLR over POBA [10]. Furthermore safety concerns have been raised recently using PCB below the knee by Katsanos *et al* who showed a worse one-year AFS rate (a composite endpoint of death and major LEA) following treatment of infra-popliteal arteries with PCBs [11], although this was not borne out from a subsequent meta-analysis by Dinh *et al.* [29]. This has led to interest in the use of novel sirolimus-delivery technologies in the periphery [30]. In the Physician initiated, prospective, non-Randomized single-center trial, investigating the safety and Efficacy of the Treatment with the Selution Sirolimus Coated Balloon in TASC C and D Tibial occlusive disease In patients with critical limb Ischemia from SinGaporE (PRESTIGE) trial (NCT04071782), Selution SLR™ was studied for the treatment of complex tibial

artery occlusive disease (100% TASC C-D; 63.3% moderate-severe calcification) in 25 patients with CLTI within a multi-ethnic Asian cohort from Singapore. Patients were complex, having high rates of co-morbidities such as diabetes (88%) and end stage renal failure (44%). Early results are promising in terms of primary patency and successful wound healing.

Limitations

Major limitations of the study were its single arm, non-randomized nature, single operator experience, relatively small sample size and self-adjudicated design without assessment quality of life metrics. No quantitative angiographic analysis was performed to look at exact lesion lengths, reference vessel diameters and minimum lumen diameters for each tibial target lesion. There was no core lab adjudication for tibial artery patency at follow-up. Furthermore, SGH is a specialized and experienced centre for lower limb salvage of diabetic patients with CLTI in Singapore with established multi-disciplinary protocols for wound care, which may limit the generalizability of our results. This study however is more representative and relevant to everyday clinical practice in Singapore and in Asian CLTI patients who have longer complex lesions, chronic CTO and heavy wall calcification.

Conclusions

The Jade™ high pressure non-compliant balloon is safe and efficacious in treating highly complex infra-popliteal atherosclerotic lesions in an otherwise challenging population of CLTI patients with a high incidence of diabetes mellitus and end stage renal failure. It is associated with highly satisfactory acute technical success, 6-month target lesion patency and one-year limb salvage. Intraprocedural complications such as vessel perforation and bailout stenting rates are low using the balloon in what are difficult lesions to treat (long CTOs with severe calcification). The 73% primary patency rate at 6 months of the tibial vessels seen does though leave room for improvement and perhaps the complementary use of rotablation and addition of drug (either paclitaxel or sirolimus based technology) to minimise NIH after adequate vessel preparation with the Jade™ are complementary techniques worth exploring in a future prospective trial.

References

1. Conte MS, Bradbury AW, Kolh P, White JV, Dick F, Fitridge R, et al. Global vascular guidelines on the management of chronic limb-threatening ischemia. *Eur J Vasc Endovasc Surg.* 2019;58(1S):1–109.
2. Mustapha JA, Finton SM, Diaz-Sandoval LJ, Saab FA, Miller LE. Percutaneous transluminal angioplasty in patients with

- infrapopliteal arterial disease: Systematic review and meta-analysis. *Circ Cardiovasc Interv.* 2016;9(5):e003468.
3. Baumann F, Fust J, Engelberger RP, Hugel U, Do DD, Willenberg T, et al. Early recoil after balloon angioplasty of tibial artery obstructions in patients with critical limb ischemia. *J Endovasc Ther.* 2014;21(1):44–51.
 4. Weintraub WS. The pathophysiology and burden of restenosis. *Am J Cardiol.* 2007;100(5A):3K–9 K.
 5. Rastan A, Brechtel K, Krankenberg H, Zahorsky R, Tepe G, Noory E, et al. Sirolimus-eluting stents for treatment of infrapopliteal arteries reduce clinical event rate compared to bare-metal stents: Long-term results from a randomized trial. *J Am Coll Cardiol.* 2012;60(7):587–91.
 6. Baumann F, Bloesch S, Engelberger RP, Makaloski V, Fink H, Do DD, et al. Clinically-driven need for secondary interventions after endovascular revascularization of tibial arteries in patients with critical limb ischemia. *J Endovasc Ther.* 2013;20(5):707–13.
 7. Schmidt A, Ulrich M, Winkler B, Klaeffling C, Bausback Y, Braunlich S, et al. Angiographic patency and clinical outcome after balloon-angioplasty for extensive infrapopliteal arterial disease. *Catheter Cardiovasc Interv.* 2010;76(7):1047–54.
 8. Iida O, Soga Y, Kawasaki D, Hirano K, Yamaoka T, Suzuki K, et al. Angiographic restenosis and its clinical impact after infrapopliteal angioplasty. *Eur J Vasc Endovasc Surg.* 2012;44(4):425–31.
 9. Werk M, Langner S, Reinkensmeier B, Boettcher HF, Tepe G, Dietz U, et al. Inhibition of restenosis in femoropopliteal arteries: Paclitaxel-coated versus uncoated balloon: Femoral paclitaxel randomized pilot trial. *Circulation.* 2008;118(13):1358–65.
 10. Ipema J, Huizing E, Schreve MA, De Vries JPM, Unlu C. Editor's choice – Drug coated balloon angioplasty vs. standard percutaneous transluminal angioplasty in below the knee peripheral arterial disease: A systematic review and meta-analysis. *Eur J Vasc Endovasc Surg.* 2020;59(2):265–75.
 11. Katsanos K, Spiliopoulos S, Kitrou P, Krokidis M, Paraskevoopoulos I, Karnabatidis D. Risk of death and amputation with use of paclitaxel-coated balloons in the infrapopliteal arteries for treatment of critical limb ischemia: A systematic review and meta-analysis of randomized controlled trials. *J Vasc Interv Radiol.* 2020;31(2):202–12.
 12. Brodmann M, Froehlich H, Dorr A, Gary T, Portugaller RH, Deutschmann H, et al. Percutaneous transluminal angioplasty versus primary stenting in infrapopliteal arteries in critical limb ischemia. *Vasa.* 2011;40(6):482–90.
 13. Rutherford RB, Baker JD, Ernst C, Johnston KW, Porter JM, Ahn S, et al. Recommended standards for reports dealing with lower extremity ischemia: Revised version. *J Vasc Surg.* 1997;26(3):517–38.
 14. Dattilo R, Himmelstein SI, Cuff RF. The COMPLIANCE 360 degrees Trial: A randomized, prospective, multicenter, pilot study comparing acute and long-term results of orbital atherectomy to balloon angioplasty for calcified femoropopliteal disease. *J Invasive Cardiol.* 2014;26(8):355–60.
 15. Core R, Team R. A language and environment for statistical computing. Vienna, Austria: R Foundation for Statistical Computing; 2018.
 16. Nakabayashi K, Ando H, Kaneko N, Shiozaki M, Sunaga D, Matsui A, et al. A novel lesion crossing technique: Balloon deployment using FORcible Manner (BADFORM) technique. *Catheter Cardiovasc Interv.* 2017;90(7):1161–5.
 17. Romiti M, Albers M, Brochado-Neto FC, Durazzo AE, Pereira CA, De Luccia N. Meta-analysis of infrapopliteal angioplasty for chronic critical limb ischemia. *J Vasc Surg.* 2008;47(5):75–81.
 18. Bosiers M, Hart JP, Deloose K, Verbist J, Peeters P. Endovascular therapy as the primary approach for limb salvage in patients with critical limb ischemia: Experience with 443 infrapopliteal procedures. *Vascular.* 2006;14(2):63–9.
 19. Schanzer A, Hevelone N, Owens CD, Belkin M, Bandyk DF, Clowes AW, et al. Technical factors affecting autogenous vein graft failure: Observations from a large multicenter trial. *J Vasc Surg.* 2007;46(6):1180–90.
 20. Diehm N, Rohrer S, Baumgartner I, Keo H, Do D, Kalka C. Distribution pattern of infrageniculate arterial obstructions in patients with diabetes mellitus and renal insufficiency – Implications for revascularization. *Vasa.* 2008;37(3):265–73.
 21. Nakamura S, Colombo A, Gaglione A, Almagor Y, Goldberg SL, Maiello L, et al. Intracoronary ultrasound observations during stent implantation. *Circulation.* 1994;89(5):2026–34.
 22. Seth A, Gupta S, Pratap Singh V, Kumar V. Expert opinion: Optimising stent deployment in contemporary practice: The role of intracoronary imaging and non-compliant balloons. *Interv Cardiol.* 2017;12(2):81–4.
 23. Romagnoli E, Sangiorgi GM, Cosgrave J, Guillet E, Colombo A. Drug-eluting stenting: The case for post-dilation. *JACC Cardiovasc Interv.* 2008;1(1):22–31.
 24. Abele JE. Balloon catheters and transluminal dilatation: Technical considerations. *AJR Am J Roentgenol.* 1980;135(5):901–6.
 25. Brodie BR, Cooper C, Jones M, Fitzgerald P, Cummins F. Postdilatation Clinical Compartment Study I. Is adjunctive balloon postdilatation necessary after coronary stent deployment? Final results from the POSTIT trial. *Catheter Cardiovasc Interv.* 2003;59(2):184–92.
 26. Kan J, Ge Z, Zhang JJ, Liu ZZ, Tian NL, Ye F, et al. Incidence and clinical outcomes of stent fractures on the basis of 6,555 patients and 16,482 drug-eluting stents from 4 centers. *JACC Cardiovasc Interv.* 2016;9(11):1115–23.
 27. Raja Y, Routledge HC, Doshi SN. A noncompliant, high pressure balloon to manage undilatable coronary lesions. *Catheter Cardiovasc Interv.* 2010;75(7):1067–73.
 28. Felekos I, Karamasis GV, Pavlidis AN. When everything else fails: High-pressure balloon for undilatable lesions. *Cardiovasc Revasc Med.* 2018;19(3 Pt A):306–13.
 29. Dinh K, Gomes ML, Thomas SD, Paravastu SCV, Holden A, Schneider PA, et al. Mortality after paclitaxel-coated device use in patients with chronic limb-threatening ischemia: A systematic review and meta-analysis of randomized controlled trials. *J Endovasc Ther.* 2020;1526602820904783.
 30. Soon SXY, Chong TT, Yap CJQ, Lee SQW, Yap HY, Shulze J, et al. Role of sirolimus-coated angioplasty balloons: A review of current status and emerging applications in peripheral arterial disease. *J Cardiol & Cardiovasc Ther.* 2020;15(5):555924. <https://doi.org/10.19080/JOCCT.2020.15.555924>

History

Submitted: 13.04.2020

Accepted after revision: 04.06.2020

Published online: 22.07.2020

Conflicts of interests

No conflicts of interest exist.

ORCID

Tjun Yip Tang

 <https://orcid.org/0000-0002-8524-7912>

Correspondence address

Tjun Yip Tang MD FRCS FAMS
Associate Professor Duke-NUS Medical School
Department of Vascular Surgery
Singapore General Hospital
20 College Road
Singapore 169856
Singapore

tang.tjun.yip@singhealth.com.sg